


Contents lists available at [ScienceDirect](https://www.sciencedirect.com)

Urology Case Reports

journal homepage: www.elsevier.com/locate/eucr

Pediatrics

Cobb's collar and chronic renal failure

Carolina S. Martins^a, José Carnevale^a, Nilton C. Vicente^a, Luiz G. Freitas Filho^{b,a,*}

^a PUCC – Pontifícia Universidade Católica de Campinas, Brazil

^b Universidade Federal de São Paulo, Brazil



ARTICLE INFO

Keywords:

Bulbar urethra
Cobb's collar
Congenital strictures
Chronic renal failure

Introduction

Cobb's collar is a membranous stricture of the bulbar urethra, often underestimated and non-diagnosed.¹ Dewan presented evidence of a common morphological diagnosis for patients presenting with congenital obstructive posterior urethral membrane.² The term COPUM (Congenital obstructive posterior urethral membrane) has been suggested in that two distinct pathologies should be distinguished. In boys with a COPUM, the obstructing membrane is just distal to the external sphincter and reinforced by folds extending down from the verumontanum, which when split resemble the valve obstruction suggested by Young.³ The COPUM is probably due to persistence of the attachment of the verumontanum to the anterior wall of the posterior urethra. Cobb described a congenital narrowing of the bulbar urethra that probably represents an embryological process different from that of the COPUM. Cobb's collar is most likely due to a partially persistent urogenital membrane.²

We report the case of a child with Cobb's collar having had, in other Service, endoscopic fulguration as if being treated for posterior urethral valve. When undergoing cystoscopy, the obstructive ring was found to be fully intact as if never treated before. The child evolved into chronic renal failure.

Material and methods

Case

A 10 year-old boy, born in the 32nd week of pregnancy, weighing 1485g. Antenatal ultrasonography showed bilateral ureteral–hydronephrosis, trabecular bladder and severe oligoamnios. Voiding

cystourethrography was labelled, in the child's city of origin, as a posterior urethral valve diagnosis (Fig. 1). He remained hospitalized for 70 days in the neonatal ICU due to prematurity. At three months of age he underwent vesicostomy; he had several urinary tract infection events, in addition to being readmitted several times for metabolic disorders. A first valve fulguration attempt was made at the child's original hospital, when the child was 5 months old. At six months he underwent bilateral inguinal herniorrhaphy and gastrostomy due to difficulty to both swallow and gain weight. At the age of one year he had gastric fundoplication by Nissen's technique. At the age of 6 years he underwent a new attempt at fulguration of the posterior urethral valves that were described as being of YOUNG type III; the vesicostomy was maintained. The child was then referred to our Service where the cystoscopy enabled Cobb's collar diagnosis to be made (Fig. 2). He underwent fulguration of the lesion and closure of the vesicostomy (Fig. 3). Since then he has had a proper urinary stream; follow-up is being made by the pediatric Nephrology and Endocrinology teams.

Comment

Bulbar urethral stricture was described by COBB et al., in 1968.¹ Existence of the abnormality was discussed in the literature which resulted in the suggestion that it would not be an isolated abnormality, but part of the external sphincter.⁴ Our case give evidence of the existence of a structure separated from the external sphincter, apart from the verumontanum, which distinguished it from COPUMs. Young classified urethral obstructions by considering the diaphragm “valves” with a hole in the center as posterior urethral valves type III.³ The valve appearance is created by folds that run down from the distal portion of the verumontanum. Dewan et al. believe there would be two types of

* Corresponding author. Rua Batista Cepelos 87 ap 61 04109-120, São Paulo, Brazil.

E-mail addresses: carolmartins38@yahoo.com.br (C.S. Martins), carnevalejose@hotmail.com (J. Carnevale), niltoncrepaldi@terra.com.br (N.C. Vicente), luizfreitasepm@gmail.com.br (L.G. Freitas Filho).

<https://doi.org/10.1016/j.eucr.2018.03.017>

Received 3 March 2018; Received in revised form 21 March 2018; Accepted 23 March 2018

Available online 27 March 2018

2214-4420/ © 2018 The Authors. Published by Elsevier Inc. This is an open access article under the CC BY-NC-ND license (<http://creativecommons.org/licenses/by-nc-nd/4.0/>).

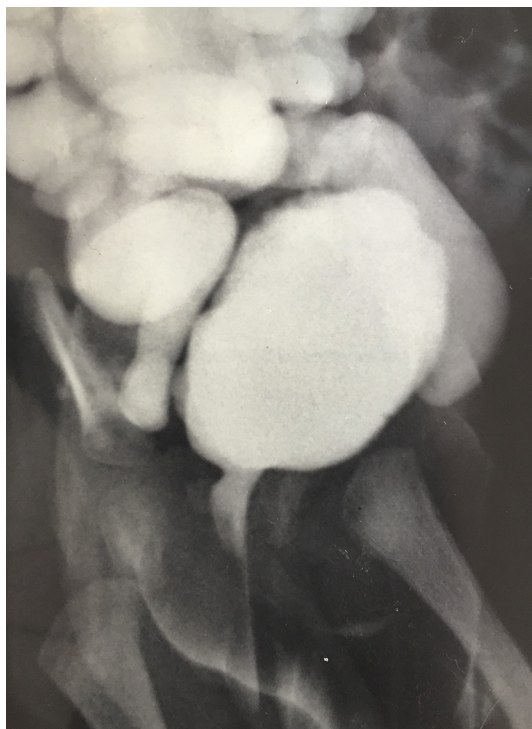

Fig. 1. CUM showing urethral obstruction trabecular bladder and vesicoureteral reflux grade V.

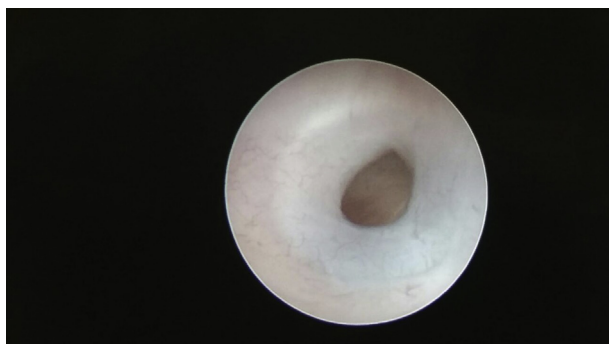


Fig. 2. Typical COBB's COLLAR image.

congenital urethral obstruction.² In the first type there would be a membrane connecting the distal verumontanum to the anterior wall of the posterior urethra. Such membranous obstruction is capable of

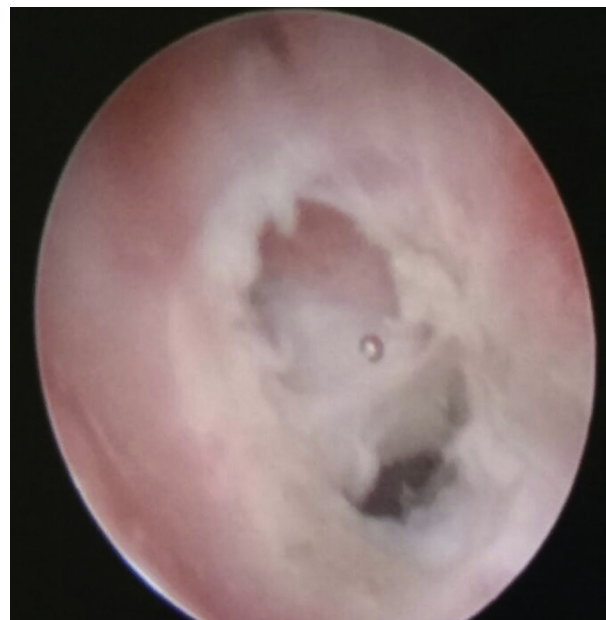


Fig. 3. COBB's COLLAR following fulguration.

causing a distal prolapse. In the second type of obstruction the membrane is independent from the verumontanum, like in our case, and may represent a portion of the urogenital sinus.²

Our case had presented urinary flow obstruction since the antenatal period with a behavior similar to that of children with COPUM, however the COBB's collar was inadequately treated because perhaps having embryonic origin other than COPUM, the Cobb's collar may be more likely to have recurred.

Although quite rare, pediatric urologists must be aware of the existence of Cobb's collar that may cause obstruction in the perinatal period and have an unexpectedly unfavorable evolution.

References

1. Cobb BG, Wolf Jr JA, Ansell JS. Congenital stricture of the proximal urethral bulb. *J Urol.* 1968;99:629–631.
2. Dewan PA, Keenan RJ, Morris LL, LeQuesne GW. Congenital urethral obstruction: Cobb's collar or prolapsed congenital obstructive posterior urethral membrane (COPUM). *Br J Urol.* 1994;73:91–96.
3. Young HH, Frontz RH, Baldwin TC. Congenital obstruction of the posterior urethra. *J Urol.* 1919;3:289–365.
4. Cranston D, Davies AH, Smith JC. Cobb's collar – a forgotten entity. *Br J Urol.* 1990;66:294–296.