



Pediatrics

Spinal cord tumor leading to urinary retention resulting from *Schistosoma mansoni* infection in a child

Luiz G. Freitas Filho^{a,b,*}, Ana Carolina Carvalho da Fonseca^b, Raphael Miranda Magalhães^b,
Taynara Roberta Guerreiro Paiva^b, Giselle Coelho^c, Maria Cristina Gomes Abreu^b

^a Department of Urology, Universidade Federal de São Paulo, Brazil

^b Department of Pediatric Surgery, Hospital Santa Marcelina, Brazil

^c Department of Neurosurgery, Hospital Santa Marcelina, Brazil

ARTICLE INFO

Keywords:

Schistosomiasis
Schistosoma mansoni
Neurogenic bladder
Spinal cord diseases

ABSTRACT

Schistosoma mansoni is an endemic disease in Brazil. It rarely affects the central nervous system, particularly in children. We report the case of a child that presented with an acute spinal cord compression condition, resulting from a mass that proved to be a granuloma caused by a *Schistosoma mansoni* infection. Proper treatment had no effect on the regression of urological symptoms and the child had to undergo a Mitrofanoff principle.

Introduction

Described for the first time by Théodore Bilharzin 1851, *Schistosoma hematobium*, the worm responsible for “Egyptian hematuria”, causes a parasitosis that used to be, and still is, a major public health problem in the River Nile valley.¹ *Schistosoma* eggs were found in the viscera of Egyptian mummies who lived about 1250 years B.C. It is also reported that in the city of Cehang-Iha, in China, *Schistosoma japonicum* eggs were found in a cadaver believed to be about 2000 years old. It was not until Sambon studies, in 1907, that it became clear that the worms found in Brazil differed from those found in other parts of the world as they have a lateral spicule and lodge in the blood vessels of the digestive system.² They were named *Schistosoma mansoni*. Schistosomiasis is an infection caused by flatworms, from the group of trematodes, called Schistosomes. Five species of Schistosomes cause infection in humans. *Schistosoma hematobium*, which infects the urinary tract, including the bladder. This species is widely distributed across the African continent and occurs in some countries in the Middle East, Turkey and India. *Schistosoma mansoni*, *Schistosoma japonicum*, *Schistosoma makongi* and *Schistosoma intercalatum* infect the intestine and liver. *Schistosoma mansoni* is the only *Schistosoma* found in the western hemisphere, being found in parts of South America and the Caribbean.² Slave trade is considered to be the main factor accounting for the introduction of the disease in

Brazil. *Schistosomiasis mansoni* is endemic in a vast portion of the Brazilian territory and is considered to be a severe public health problem, as it affects millions of people in many and different severe forms. Considering that *Schistosoma mansoni* is rarely located in the nervous system, we report the case of a child in whom it manifested as an acute spinal cord compression syndrome.

Case presentation

A male child, 4 years old, was brought by his parents to our institution because of a progressive difficulty to walk, which started some 10 days before the medical visit. Simultaneously, he started having difficulty to evacuate, with a disorder in his urinary flow, dribbling urine practically all the time. His behavior led to suspicion of autism, which was being investigated. The Neurosurgical team was called and asked for a magnetic resonance that showed a formation extending into the spinal cord, from T12 to L2, measuring 3,8 cm in longitudinal length and axial thickness of 1,8 cm (Fig. 1). Brain scanning was normal. The child underwent a surgical intervention for suspicion of either anependymoma or a medullary astrocytoma. An approach using a Zeiss ARTEVO 800 microscope, revealed the medullary cone to be engorged, with tortuous vessels on the surface and a medullary lesion with a yellowish surface, fully separated from the spinal cord, however compressing it.

* Corresponding author. Rua Batista Cepelos 87 – ap 61, 04109-120, São Paulo, Brazil.

E-mail addresses: luizfreitasepm@gmail.com, luiz.freitas@unifesp.br (L.G. Freitas Filho), carolfonsecacarvalho@gmail.com (A.C. Carvalho da Fonseca), raphaelmmster@gmail.com (R.M. Magalhães), taynarapaiva@gmail.com (T.R. Guerreiro Paiva), gigicoelho7@hotmail.com (G. Coelho), cristinagabreu@uol.com.br (M.C. Gomes Abreu).

<https://doi.org/10.1016/j.eucr.2020.101479>

Received 30 September 2020; Received in revised form 26 October 2020; Accepted 1 November 2020

Available online 5 November 2020

2214-4420/© 2020 Published by Elsevier Inc. This is an open access article under the CC BY-NC-ND license (<http://creativecommons.org/licenses/by-nc-nd/4.0/>).

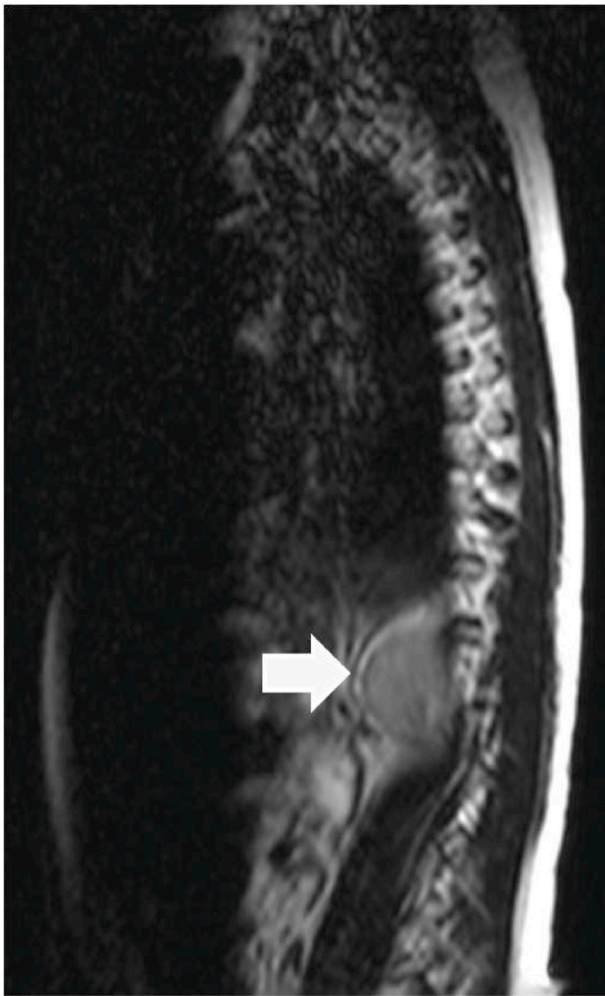

Fig. 1. MRI showing a formation extending into the spinal cord (arrow), from T12 to L2, measuring 3,8 cm in longitudinal length and axial thickness of 1,8 cm.

The lesion was excised after the entire arachnoid, that was too thick, had been detached. A microscopic examination of a fragment that had been frozen during the intervention, revealed it, actually, to be an inflammatory process rather than a tumor. The definitive anatomopathological examination of the surgical specimen showed a granulomatous inflammatory process typical of *Schistosoma mansoni* infections (Fig. 2). He was treated on Praziquantel, on a 60 mg/Kg single dose. Thorough anamnesis revealed that the child had been swimming a few months earlier in a place suspected of existence of the worms. Following the intervention

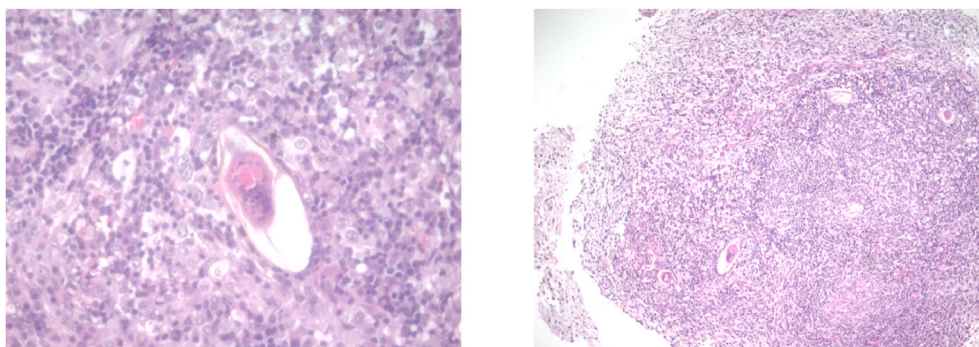


Fig. 2. Transverse section of medullary lesion showing a chronic granulomatous process typical of *Schistosoma mansoni* infections. In the center of the slide there is a granuloma containing remains of the *Schistosoma mansoni* egg involved by a periovarial inflammatory reaction containing neutrophils and lymphocytes.

he slowly started walking again, however always limping on the right leg. He still needed to take laxatives to evacuate and, as he still had urinary incontinence; he was discharged from hospital with a urinary catheter. An ultrasound examination prior to discharge showed mild bilateral hydronephrosis and a thickened wall bladder. When asked to empty his bladder after the examination, the child was unable to void. On different occasions, during a four-month period, we tried to remove the catheter but the child was never able to void. The intermittent urinary catheterization attempt failed as a result of the child's persistent resistance. Five months following the neurosurgical intervention we decided to build a urinary catheterization diversion, interposing the cecal appendix between the bladder and the umbilicus (Mitrofanoff principle). The child accepted the catheterization relatively well; currently he still has mild bilateral hydronephrosis and a thickening of the bladder wall. His renal function is currently normal, still has difficulty to evacuate, still limps, about 10 months after the onset of symptoms.

Discussion

Involvement of the spinal cord in a *Schistosoma mansoni* infection is very rare, particularly in children. It is important to recognize that affection of the spinal cord can be potentially reversed provided treatment is established early enough, which unfortunately did not occur with our patient.^{3,4}

In some cases urological symptoms can be the initial and main manifestation, reason why it is important that urologists be attentive to this kind of disease.

Our patient came to our Department presenting with the typical manifestations of a medullary compression syndrome. The anatomopathological examination revealed it to be a chronic granulomatous lesion, typical of *Schistosoma mansoni* infections. Posterior thorough anamnesis confirmed that the child had been attending an endemic area of the disease.

Even after treatment was established there was no complete regression of the lesions and the child had to undergo a surgical intervention for an intermittent urinary catheterization system to be inserted.

Currently the child still has sequels from the lesion which comes to show that neurological deficits, even when the disease is treated, may persist.⁵

Conclusion

Children with an acute form of Spinal Cord Schistosomiasis may present persistent neurological deficits, behaving just like other patients with different causes of Spinal Cord Diseases.

References

1. Ziskind B. La bilharziose urinaire en ancienne Égypte. *Néphrol Thérapeutique*. 2009;5: 659–661. <https://doi.org/10.1016/j.nephro.2009.06.001>.
2. Sambon LW. Descriptions of some new species of animal parasites. In: *Proceedings of the Zoological Society, London*. 1907:282–283.
3. Ferrari TC, Moreira PR, Cunha AS. Spinal cord schistosomiasis. A prospective study of 63 cases emphasizing clinical and therapeutics aspects. *J Clin Neurosci*. 2004;11: 246–253. <https://doi.org/10.1016/j.jocn.2003.05.006>.
4. Haribhai HC, Bhigjee AI, Bill PL, et al. Spinal cord schistosomiasis. A clinical laboratory and radiological study, with a note on therapeutic aspects. *Brain*. 1991; 114:709–726. <https://doi.org/10.1093/brain/114.2.709>.
5. Gomes CM, Hisano M, Machado LR, Figueiredo JÁ, Lucon AM, Trigo-Rocha FE. Urological manifestation of chronic schistosoma lmyeloradiculopathy. *BJU Int*. 2005; 96:853–856. <https://doi.org/10.1111/j.1464-410X.2005.05726.x>.