

Pediatrics

The XY female and SWYER syndrome

Karine F. Meyer^a, Luiz G. Freitas Filho^{b,*}, Karina I. Silva^a, Pedro A. Trauzcinsky^a, Cristina Reuter^a, Maria Beatriz M. Souza^b

^a Universidade de Blumenau, Brazil

^b Universidade Federal de São Paulo, Surgery Department, Brazil



ARTICLE INFO

Keywords:

Swyer syndrome
Gonadal dysgenesis
Primary amenorrhea
46 XY

ABSTRACT

SWYER syndrome or pure gonadal dysgenesis is a disease in which individuals with a female phenotype, with female external genital organs, have a 46 XY karyotype and streak gonads that ought to be removed given their high malignization potential. We present the case of a patient with Swyer syndrome, and compare them with other cases of patients with a 46 XY karyotype, phenotypically female, such as in Congenital Adrenal Hyperplasia from deficiency of the 17 α hydroxylase/17-20 Lyase enzyme and in the Congenital Androgenic Insensitivity Syndrome.

Introduction

Sexual differentiation depends on a series of complex events that first lead to the gonadal definition, then to the differentiation of the internal genital organs and after that, to differentiation of the external genital organs.

The presence of a Y chromosome, leads through a “switch gene” present in its short branch called SRY, to the formation of the testis. A few other factors named “Testis Determining Factors” (TDF) will also lead to the gonadal differentiation in the development of the testis tissue. Sertoli cells, found in the testis tubules, produce a glycoprotein known as anti-Müllerian hormone that triggers regression of the structures originated from the paramesonephric duct (tubes, uterus and vagina). Whereas the Leydig cells, found in the testis interstitium, secrete the fetal testosterone that, through a paracrine action, convert the mesonephric duct into deferent duct, seminal vesicle and epididymis. The testosterone is then converted into dihydrotestosterone by action of the 5- α reductase enzyme, causing masculinization of the external genital organs.¹ The ovarian tissue develops in the absence of TDF and as a result of the anti-testis action of genes DAX 1, Rspo1 and WNT4. The ovaries produce no hormones during the fetal life and the development of the female genitalia is not dependent on hormone production.¹

Three different conditions are the ones that most frequently lead to the development of a female phenotype in a person with the 46 XY karyotype: Congenital Androgenic Insensitivity Syndrome (CAIS), Congenital Adrenal Hyperplasia (CAH) from deficit of the 17- α hydroxylase/17-20 lyase enzyme and the complete gonadal dysgenesis

also known as Swyer syndrome.¹⁻³

We report a case of Swyer Syndrome and discuss the differential diagnosis of such dysgenesis against the two other conditions.

Material and methods

Case report

Case 1: A thirty-one year old female; at age 15 started hormone replacement due to primary amenorrhea, with only one previous vaginal bleeding event. At 20 years had her first assessment by an endocrinologist: Estrone 62 pg/mL; Estradiol 31,8 pg/mL. Bone Density Test: lumbar spine (L1-L) z-score -2,6; femoral neck z-score -1,1, total femur z-score -1,0. CT Scanning: ovarian hypoplasia, uterus of small dimensions and hepatic steatosis. |Karyotype confirmed in two occasions: 46 XY. Molecular analysis of the SRY and AR genes, using the PCR-SSCP method, did not reveal any mutations. First urological assessment on 27/11/2017: Weight 101.5 Kg, Height 167 cm, BMI 36.4 Kg/m². Under general anesthesia: normal vagina, normal external genitalia (Fig. 1). Laparoscopy: female internal genitalia of infantile aspect. Bilateral oophorectomy performed. AP: Atrophic ovaries with calcification foci. Normal uterine tubes.

Comment

In 1955 Swyer described two cases of “male pseudohermaphroditism”. In reference to two women with a XY karyotype presenting

* Corresponding author. Rua Batista Cepelos 87, ap 61, 04109-120, São Paulo, Brazil. +55 11 983231200.

E-mail addresses: karine_meyer@uol.com.br (K.F. Meyer), luizfreitasepm@gmail.com, luizfreitasf@hotmail.com (L.G. Freitas Filho), karinailheu@gmail.com (K.I. Silva), pedrotrau@hotmail.com (P.A. Trauzcinsky), cristinareuter@gmail.com (C. Reuter), mariabia7@hotmail.com (M.B.M. Souza).

<https://doi.org/10.1016/j.eucr.2019.100939>

Received 28 May 2019; Received in revised form 5 June 2019; Accepted 6 June 2019

Available online 07 June 2019

2214-4420/© 2019 The Authors. Published by Elsevier Inc. This is an open access article under the CC BY-NC-ND license (<http://creativecommons.org/licenses/by-nc-nd/4.0/>).

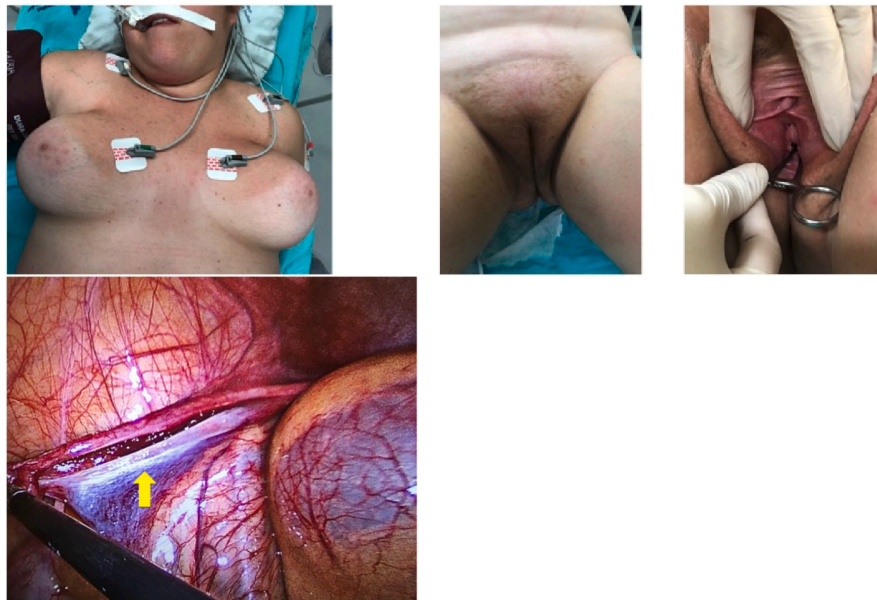


Fig. 1. Case 1 showing well developed breasts, female external genital organs with normal vagina and streak gonad (arrow).

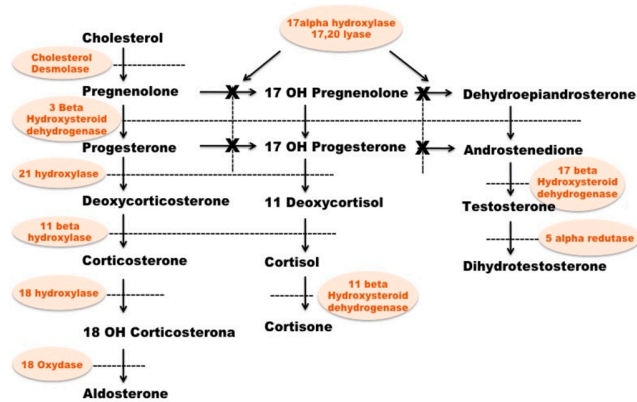


Fig. 2. Biosynthesis of the adrenocortical hormones showing blockage of the 17- α hydroxylase/17-20- Lyase enzyme.

primary amenorrhea, tall stature and female external genitalia, although one of the patients had an enlarged clitoris, but a normal vagina.² Henceforth such complete gonadal dysgenesis has been named Swyer Syndrome.

It affects approximately between 1:30.000 and 1:80.000 born children that have a female phenotype, no genital ambiguity at birth, and normal Müllerian structures. It is usually revealed in adolescence, with pubertal delay and amenorrhea, since the gonads have no reproductive or hormonal potential, as can be seen in our patient.¹

Since Swyer Syndrome carries a high incidence of gonadoblastoma and “germ cell malignancies” a gonadectomy ought to be performed as soon as the diagnosis is made, as in the case described (Fig. 1).

CAH is a rare condition that stems from a defect in the biosynthesis of the adrenocortical hormones. CAH carries several genetic mutations in the enzymes responsible for the steroidogenesis (Fig. 2). Because of the enzymatic defect only a small amount of cortisol is produced and as a result, there is no negative feedback controlling the ACTH, resulting

in an excess production of ACTH besides an exaggerated production of steroid precursors that precede the faulty enzyme. CAH ought to be a differential diagnosis in children with genital ambiguities, infantile sexuality, hypogonadism or hypertension, particularly when associated with dehydration episodes. The most common form is 21- α hydroxylase deficiency that can be diagnosed at birth by the presence of virilization in girls or presence of the salt losing syndrome in both genders. Deficiency of 11- beta hydroxylase is less common and deficiency of 17-α hydroxylase/17,20-lyase appears later in adolescence or in adult life accounting for only 1% of the CAH cases with an approximate rate of 1:1.000.000 of born children (Fig. 2). Deficiency of 17-α hydroxylase/17,20-lyase, when occurring in XY persons, leads to the development of a completely female phenotype, with genital infantilism and whose diagnosis is, as a rule, established by the presence of amenorrhea and occasionally the presence of a bilateral inguinal hernia whose correction reveals a testicle.³ Given the accumulation of mineralocorticoids, such children tend to present a hypertension that is difficult to treat. Like in Swyer Syndrome those children are phenotypically female, however, they have a testicle that is histologically normal and that will usually be found while the inguinal hernia is treated.⁴

Complete androgen insensitivity syndrome (CAIS) is a rare disease, whose rate ranges between 1:40.000 and 1:60.000 births. Like in the two preceding conditions the karyotype is 46 XY and the patient is phenotypically female. Like in the CAH there are two histologically normal testicles, i.e., there will be a complete regression of the Müllerian organs (tubes, uterus and vagina), however with no virilization of the organs that depend on the testosterone action and whose serum values will be extremely high.⁵

Fig. 3 shows the different findings noted in patients with a feminine phenotype and with 46 XY karyotype; it can be said that they are differentiated by the presence of hypertension in the CAH, the high levels of Testosterone in CAIS and the gonadal dysgenesis in Swyer Syndrome.

Treatment of Swyer Syndrome is similar to that of other causes of ovarian failure in which puberty is induced with estrogens to develop the secondary sexual characteristics and keeping long term estrogens and progesterone therapy.

	Karyotype	Phenotype	Gonads	Müllerian organs	Special
SWYER	46 XY	Female	Streak	Yes	Dysgenesis
CAH DEF 17α HYDROXYLASE 17,20 Lyase	46 XY	Female	Testis	No	Hypertension
CAIS	46 XY	Female	Testis	No	High Testosterone

Fig. 3. Main findings of the three conditions in which 46 XY karyotype patients have a feminine phenotype.

In all three conditions the patient is phenotypically feminine, and no attempt of sex change is ever discussed, showing that the karyotype is simply one of the aspects within the complex decision of choosing the sex in which a child is raised.

References

1. Michala L. Creighton SM – the XY female. *Best Pract Res Clin Obstet Gynaecol.* 2010;24:139–148.
2. Swyer GI. Male pseudohermaphroditism: a hitherto undescribed form. *Br Med J.* 1955;2:709–712.
3. Freitas Filho LG, Carnevale J, Melo CER, Laks M, Miranda EG. Sigmoid reconfigured vaginal construction in children. *J Urol.* 2001;166:1426–1428.
4. Mula-Abed WA, Pambinezhuth FB, Al-Kindi MK, Al-Busaidi NB, Al-Muslahi HN, Al-Lamki MA. Congenital adrenal hyperplasia due to 17-alpha-hydroxylase/17,20-lyase deficiency presenting with hypertension and pseudohermaphroditism; first case report from Oman. *Oman Med J.* 2014;29:55–59.
5. Nunes E, Rodrigues C, Geraldes F, Ágrias F. Differentiating Swyer syndrome and complete androgen insensitivity syndrome: a diagnostic dilemma. *J Pediatr Adolesc Gynecol.* 2014;27:e67–e68.